

Pre-Centralization Soft Tissue Distraction for Bayne Type IV Congenital Radial Deficiency in Children

Sanjeev Sabharwal, MD,* Anthony L. Finuoli, DO,† and Fereydoon Ghobadi, MD†

Abstract: There are several surgical options for the treatment of severe congenital radial deficiency. The aim of the current study was to evaluate the results of a staged protocol consisting of gradual soft tissue distraction with an Ilizarov external fixator followed by centralization of the ulna. Three patients (four extremities) with Bayne type IV radial club hand were treated at an average age of 18 months. At a follow-up of 26 months, an average correction of 72 degrees in the hand-forearm angle and an improvement of 19 mm in the hand-forearm position were obtained. There were no cases of neurovascular compromise, wound infection, carpal resection, or ulnar shortening. All families were pleased with the results. These findings suggest that a staged surgical approach is a technically feasible alternative in the treatment of severe congenital radial club hand deformity in young children.

Key Words: radial club hand, Ilizarov, bilobed flap, soft tissue distraction

(*J Pediatr Orthop* 2005;25:377-381)

Congenital radial club hand or longitudinal radial deficiency is characterized by radial deviation of the hand, significant shortening of the forearm, and generalized underdevelopment of the extremity.¹⁻³ The thumb is usually absent or hypoplastic and the ulna is typically 60% of normal length.⁴ The incidence of radial club hand is estimated to be 1 in 30,000 to 1 in 100,000 live births.⁵ It is bilateral in 38% to 58% of cases.⁶

Originally described in 1733 by Petit, the management of congenital radial club hand has undergone significant changes. Numerous procedures and modifications have been developed to treat this condition.⁷⁻⁹ Most reports detail the use of a single-stage treatment of this condition. Nanchahal,¹⁰ using the Kessler apparatus for soft tissue distraction followed by centralization, reported favorable results; however, some

patients who underwent centralization needed carpal wedge resections. The purpose of the current study was to evaluate the results of pre-centralization distraction lengthening of the soft tissue for Bayne type IV¹¹ congenital longitudinal radial deficiency treated over a three-year period.

MATERIALS AND METHODS

Three consecutive patients (four extremities) who underwent gradual correction of their deformities based on a staged protocol were identified. Informed consent was obtained prior to initiating the treatment protocol.

The average age at the index procedure was 18.3 (range 15-22) months. All patients had type IV deformity (Figs. 1 and 2) according to the Bayne and Klug classification system,¹ with complete radiographic absence of the radius. All patients were boys, and two right and two left extremities were involved. All affected extremities had an absent thumb. None of the patients had any previous surgical intervention of their upper extremities.

The staged protocol consisted of the use of a forearm-based resting splint to keep the wrist in maximum ulnar deviation for approximately 6 weeks. Occupational therapy with stretching exercises of the affected wrist, hand, and elbow was also prescribed. This was followed by soft tissue distraction using the Ilizarov apparatus. An appropriate-sized Ilizarov ring was mounted off a 1.5-mm reference wire placed at right angles to the ulnar shaft (Fig. 3). The proximal fixation was supplemented with 3-mm half-pins mounted off the proximal ring in a dorsal to volar direction. Distal fixation was achieved with two beaded-tip 1.5-mm Ilizarov wires placed through each of the four metacarpal shafts in a radial to ulnar direction. Distraction translation hinges were applied on the ulnar aspect of the construct connecting both rings (Fig. 4A). A distraction rod was then placed on the radial aspect between the proximal and distal rings. Also, a multi-hole Ilizarov plate was suspended off the distal ring for placement of dynamic slings used for support and mobilization of each digit (Fig. 4B). At the time of surgery, no acute correction was carried out. The family was instructed to begin distraction approximately 7 days after surgery at the rate of 1 mm per day, divided in two installments of 0.5 mm each. The rate was adjusted according to discomfort and swelling of the hand. Occupational therapy was instituted within 2 days of surgery, including range-of-motion exercises for the fingers and elbow as well as the use of dynamic slings to keep the fingers in extension. Superficial pin tract infection that was controlled with a 1-week course of oral

From *UMDNJ-New Jersey Medical School, Newark, New Jersey, and †St. Joseph's Hospital, Patterson, New Jersey.

Study conducted at University of Medicine and Dentistry of New Jersey, Newark, New Jersey, and St. Joseph's Regional Medical Center, Patterson, New Jersey.

None of the authors received financial support for this study.

Reprints: Sanjeev Sabharwal, MD, Associate Professor, Department of Orthopedics, UMDNJ-New Jersey Medical School, Doctors Office Center, 90 Bergen Street, Suite 7300, Newark, NJ 07103 (e-mail: sabharsa@umdnj.edu).

Copyright © 2005 by Lippincott Williams & Wilkins

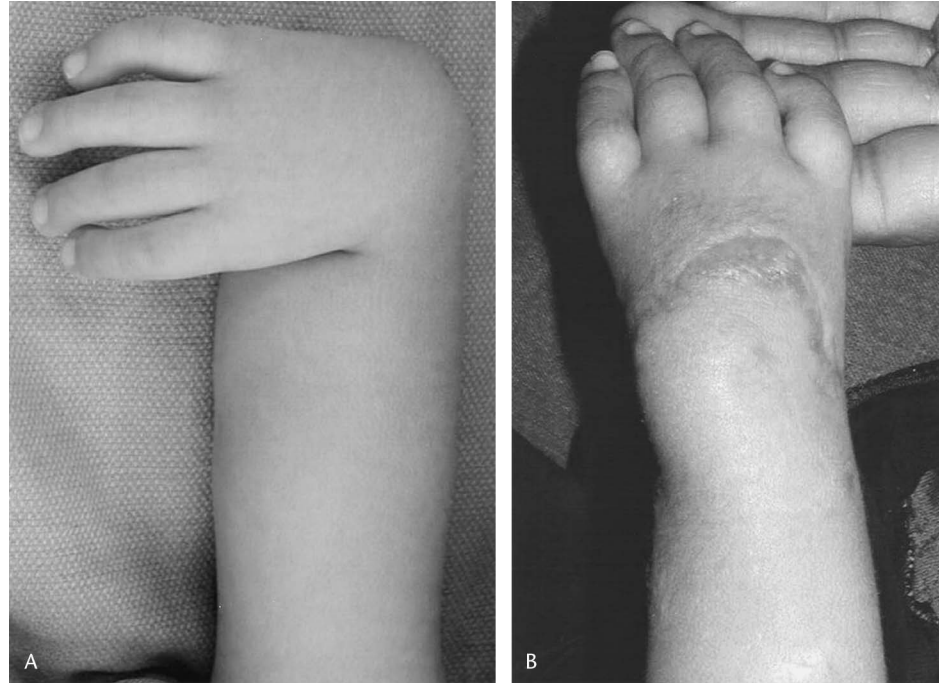

FIGURE 1. Preoperative (A) and early postoperative (B) clinical photograph of the right-sided radial longitudinal deficiency. The skin incision used for the dorsal bilobed flap can be seen in the postoperative picture. Note the spreading of the dorsal incision. This child's family refused pollicization.

antibiotics was common while the external fixator was in place.

Approximately 4 weeks after achieving the desired position of the hand and wrist, with an attempt at slight overcorrection, the Ilizarov apparatus was removed and the extremity was placed in a long-arm cast with the wrist placed in the maximally corrected position.

To decrease the possibility of secondary infection, the external fixator pin sites were allowed to heal prior to proceeding with the next phase of surgical correction. This portion of the protocol consisted of centralization of the ulna using the dorsal bilobed skin flap described by Evans^{12,13} (Fig. 1B). After confirming proper alignment of the carpus over the distal ulna, a Kirschner wire was placed in a retrograde fashion

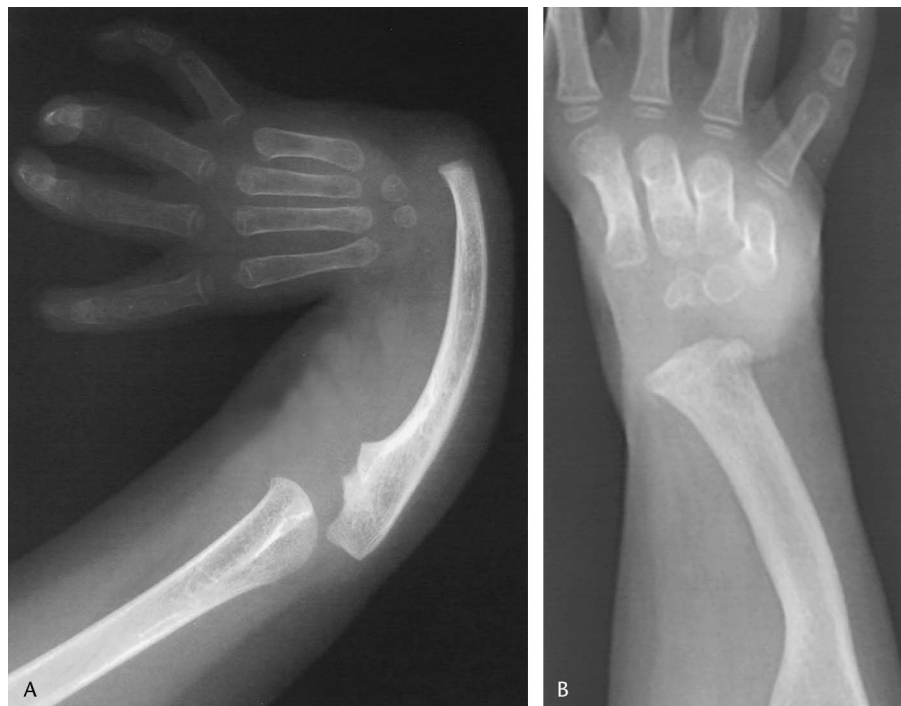

FIGURE 2. A, Preoperative anteroposterior view radiographs of the right hand and wrist of the patient shown in Figure 5, demonstrating Bayne type IV deformity. B, Followup anteroposterior view radiographs of the right hand and wrist of the patient shown in Figure 1, demonstrating correction of Bayne type IV deformity.

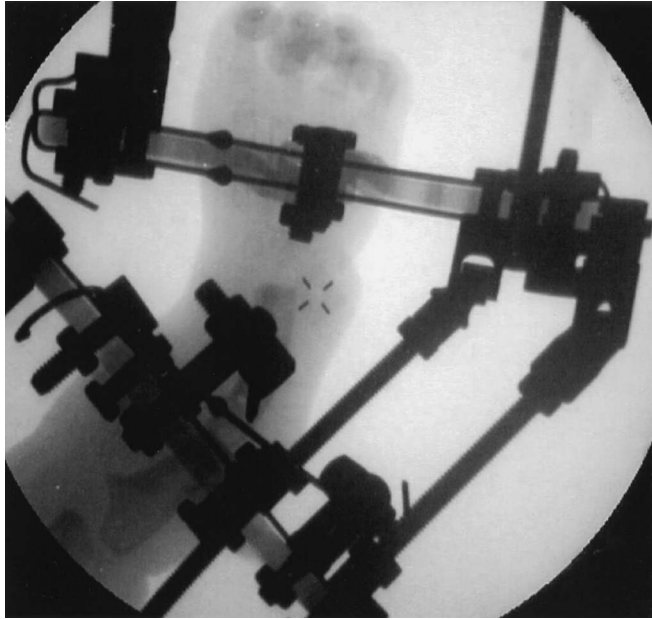


FIGURE 3. An intraoperative fluoroscopic view showing the position of the proximal and distal Ilizarov rings orthogonal to the ulnar shaft and metacarpals, respectively. The two beaded wires inserted in a radial to ulnar direction can be seen mounted off the distal ring.

through the ulna and then passed antegrade into the index or long metacarpal. No carpal resection or ulnar shortening was performed. Care was taken to preserve the distal ulnar growth plate. The distal ends of the extensor and flexor carpi ulnaris tendons were shortened and re-tensioned if redundancy was noted during surgical correction. The radial-sided tendons were hypoplastic and not lengthened or transferred. Post-

operatively, strict extremity elevation for 48 to 72 hours was carried out, thus minimizing edema.

All patients had complete absence of the thumb and were offered pollicization (Fig. 5). A rest period of 8 to 24 weeks was allowed prior to the pollicization in three of the four extremities (patients 1 and 3). The intramedullary pin was removed at the time of pollicization. The family of patient 2 refused pollicization and the intramedullary pin was removed in the office 6 weeks after surgery.

Patients were assessed radiographically by analyzing preoperative and postoperative hand and wrist radiographs as described by Manske et al.¹⁴ Two measurements were made. The hand–forearm angle (HFA) is the intersection angle between the long axis of the long finger metacarpal and the distal ulna as seen on an anteroposterior radiograph of the hand and forearm. A “minus” HFA refers to the hand and long index metacarpal axis directed in ulnar deviation with respect to the distal ulna—the more desired position. The hand–forearm position (HFP) refers to the distance in millimeters between the base of the little finger metacarpal and the distal ulna. If the proximal pole of the little finger metacarpal was ulnar to the axis of the distal ulna, the position (HFP) was recorded as positive millimeters; a change in the ulnar direction was considered an improvement in the position of the hand.

The goal was to achieve slight overcorrection with ulnar deviation of the hand and ulnar translation of the hand and wrist at the end of the treatment protocol.

RESULTS

Before surgery the average HFA and HFP were 86 degrees (range 50–108 degrees) and –9 mm (–2 to –18 mm), respectively (Tables 1 and 2). At an average follow-up of 26

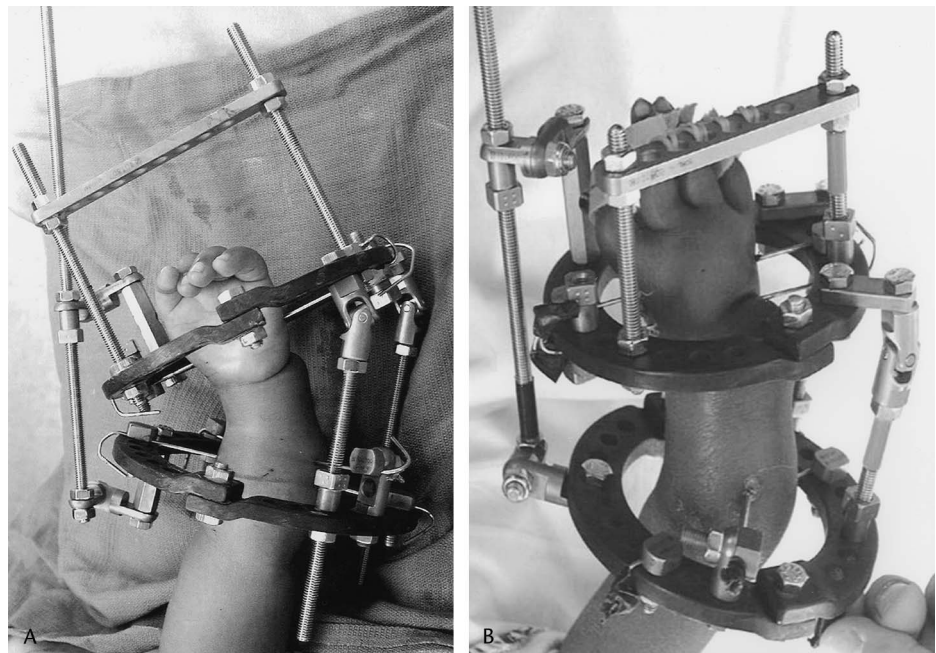


FIGURE 4. Clinical photographs of two patients during early (A) and late (B) phases of gradual correction using an Ilizarov external fixator. Note the distraction rod on the radial side and the universal hinges on the ulnar side between the two rings. A plate attached to the distal ring is used to suspend dynamic slings to maintain the fingers in extension.

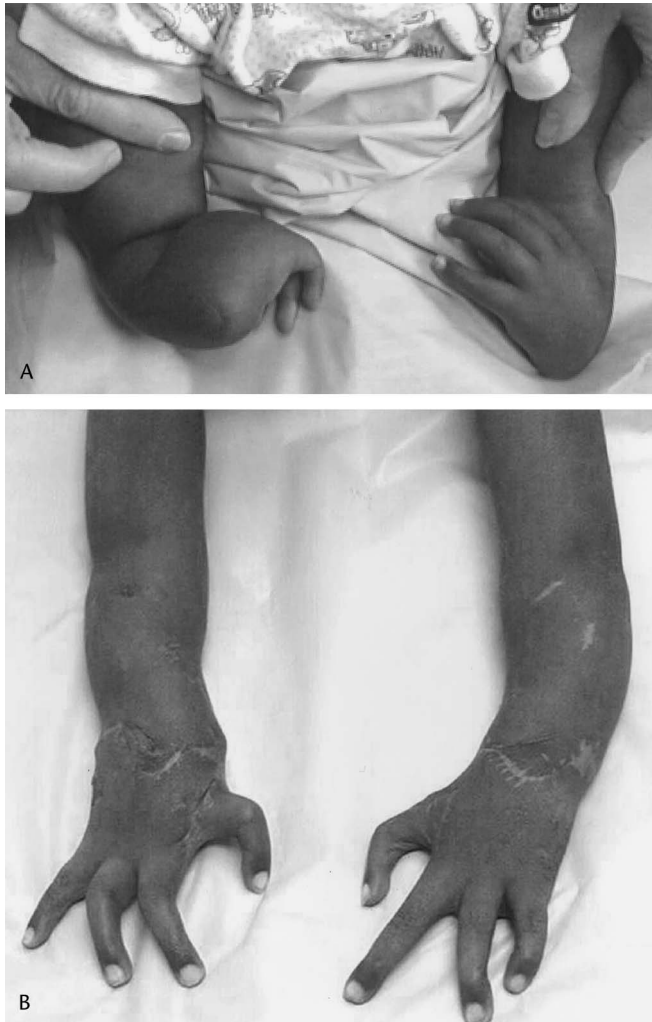

FIGURE 5. Preoperative (A) and postoperative (B) clinical photographs of a 22-month-old boy with bilateral severe congenital radial longitudinal deficiencies; he underwent three-staged reconstruction including pollicization of both extremities. Note the prominent dorsal skin incisions used for post-distraction centralization.

(range 22–34) months, the HFA had improved to an average of 14 degrees (6–26 degrees) and the HFP to +10 mm (+2 to +14 mm), an improvement of 72 degrees (44–97 degrees) and 19 mm (+4 to +31 mm), respectively.

The time spent in the external fixator ranged from 90 to 150 days (mean 130 days). There were no cases of neurovascular injury, wound infection, unplanned surgeries, or deep pin tract infections. No patient lost any finger, wrist, or elbow mobility following completion of the treatment protocol. One patient (patient 3) developed an incomplete synostosis between the index and long finger metacarpal, in the region of the Ilizarov wire insertion site. In the same patient, the intramedullary pin broke at the level of the distal ulnar growth plate during cast immobilization. The broken hardware was removed uneventfully at the time of pollicization.

All parents answered “yes” when asked, “Based on your experience, if you had a choice, would you have your child

TABLE 1. Pre- and Postoperative Hand–Forearm Angle (HFA)

Patient	Side	Age at OR (mo)	Preop HFA (°)	Postop HFA (°)	Correction HFA (°)
1	R	22	95	15	80
1	L	22	108	11	97
2	R	18	92	26	66
3	L	15	50	6	44
Average		18	86	14	72

undergo the same set of surgical interventions?” In the patients who underwent pollicization, basic key pinch function involving the pollicized digit was present.

DISCUSSION

The goals of treatment of Bayne type IV congenital longitudinal radial deficiency are to correct the wrist deformity, maintain the corrected position, provide wrist-like mobility, preserve longitudinal growth capacity of the ulna, and to achieve an acceptable cosmetic result.^{14,15} A variety of treatment protocols have been described for the treatment of congenital radial club hand, including centralization,⁹ radiolization,⁷ and microvascular epiphyseal transfer¹⁵ in younger children and distraction osteogenesis of the ulna in the older child, especially with recurrent deformity or neglected cases.^{4,16,17} While one-stage procedures subject the patient to a single operation, they are associated with the possible need for carpal resections, ulnar shortening, and sacrifice of the distal ulnar growth plate, stretch injury to the radial neurovascular structures, excessive swelling of the hand, and wound complications.

Several authors^{10,15,18} have described the concept of soft tissue distraction preceding centralization for congenital radial deficiency. Most of these reports mention unilateral or simple transfixation external fixators. Nanchahal¹⁰ used the Kessler and monolateral external fixators for soft tissue distraction in four children with congenital radial club hand. Although their patients were younger at the time of the index surgery (8 months vs. 18 months), the average improvement in hand–forearm angulation was 38 degrees compared with 72 degrees in our patients. Also, one patient in their series needed subsequent bilateral carpal wedge resections.

Smith and Greene¹⁸ described two children with radial aplasia who underwent pre-centralization soft tissue distraction using the Orthofix monolateral fixator. Radiographic parameters describing the relationship of the hand to the

TABLE 2. Pre- and Postoperative Hand–Forearm Position (HFP)

Patient	Side	Preop HFP (mm)	Postop HFP (mm)	Correction HFP (mm)
1	R	–2	+2	+4
1	L	–8	+14	+22
2	R	–9	+9	+18
3	L	–18	+13	+31
Average		–9	+10	+19

forearm were not elaborated before or after surgery. Vilkki¹⁵ used a monolateral external fixator in conjunction with a microvascular second toe transfer to the distal ulna in nine children with type IV radial aplasia. With regard to the design of the external fixator, the author commented, “the lengthening device can still be improved and it should have the potential to correct angular deformities.” The author also acknowledged unpredictable growth of the transferred bone, cosmetic concerns of the transferred skin pedicle, and technical difficulties with microvascular transfer. Residual radial deviation of the wrist averaging 20 degree was noted at follow-up.

Percutaneous techniques for deformity correction of the extremities are becoming more popular in the literature.¹⁹ Although there are reports describing the use of the Ilizarov device for ulnar lengthening in congenital radial deficiency^{4,16,17} and acquired soft tissue contractures around the wrist,²⁰ we were unable to find any report describing its use for soft tissue distraction for congenital radial club hand in young children. Sabharwal²¹ reported on the use of the Ilizarov device for reconstruction using bone transport in two cases of radial club hand-like deformity with infected nonunion of the distal radius in older patients.

We believe that the Ilizarov device offers certain advantages over previously described external fixators for pre-centralization soft tissue distraction in children with Bayne type IV congenital radial deficiency. By having the option of placing multiple bony anchors in different planes and application of translational hinges corresponding to the apex of the deformity and the ability to suspend dynamic slings off the distal end of the fixator, a more comprehensive and physiologically sound distraction can be achieved. However, one does need to be familiar with the intricacies involved in the application of the Ilizarov device. Also, compliance by the patient's family in following instructions for gradual correction is required.

By using the staged approach described in this report, one can safely distract the soft tissues and avoid several of the problems associated with reconstruction of the congenital radial club hand deformity that are often seen with other techniques. Using pre-centralization soft tissue distraction with the Ilizarov external fixator, we were able to achieve significant correction of both angulation and translation of the hand unit over the distal ulna while maintaining adequate bone stock and neurovascular function.

In terms of clinical outcome, all extremities remained in a functional position and in each case the hand was well seated over the distal ulna. We experienced two complications in the same patient (patient 3): an incomplete metacarpal synostosis and intramedullary pin fracture. The metacarpal synostosis occurred in the area of the beaded transverse wires of the Ilizarov apparatus. The clinical significance of this finding is unclear at present. Intramedullary pin breakage may have been avoided with the use of a larger-diameter pin.

A longer follow-up is required for assessing the incidence and severity of recurrent deformity. Nevertheless, our findings suggest that by using the staged approach for type IV congenital radial club hand, a significant improvement in deformity with a more functional position of the hand can be achieved while minimizing overall complications. These outcomes compare favorably to other reports in the literature.

REFERENCES

1. D'Arcangelo M, Gupta A, Schecker LR. Radial club hand. In: Gupta A, Kay SPJ, Schecker LR, eds. *The Growing Hand: Diagnosis and Management of the Upper Extremity in Children*. London: Harcourt Publishers Ltd, 2000:147–170.
2. Goldberg MJ, Meyn M. The radial clubhand. *Orthop Clin North Am*. 1976;7:341–359.
3. Tonkin MA. Radial longitudinal deficiency (radial dysplasia, radial clubhand). In: Green DP, Hotchkiss RN, Pederson WC, eds. *Green's Operative Hand Surgery*, 4th ed. Philadelphia: Churchill Livingstone, 1999:345–358.
4. Pickford MA, Schecker LR. Distraction lengthening of the ulna in radial club hand using the Ilizarov technique. *J Hand Surg [Br]*. 1998;23:186–191.
5. Flatt AE. *The Care of Congenital Hand Anomalies*, 2d ed. St Louis: Quality Medical Publishing, 1994:366–410.
6. Urban MA, Osterman LA. Management of radial dysplasia. *Hand Clin*. 1990;6:589–605.
7. Buck-Gramcko D. Radialization as a new treatment for radial club hand. *J Hand Surg [Am]*. 1985;10:964–968.
8. Lamb DW. Radial club hand. *J Bone Joint Surg [Am]*. 1977;59:1–13.
9. Watson HK, Beebe RD, Cruz NI. A centralization procedure for radial clubhand. *J Hand Surg [Am]*. 1984;9:541–547.
10. Nanchahal J, Tonkin A. Pre-operative distraction lengthening for radial longitudinal deficiency. *J Hand Surg [Am]*. 1996;21:103–107.
11. Bayne LG, Klug MS. Long-term review of the surgical treatment of radial deficiencies. *J Hand Surg [Am]*. 1987;12:169–179.
12. Evans DM, Gateley DR, Lewis JS. The use of a bilobed flap in the correction of radial club hand. *J Hand Surg [Am]*. 1995;20:333–337.
13. Pilz SM, Muradin MSM, Van Der Meulen JJNM, et al. Evaluation of five different incisions for correction of radial dysplasia. *J Hand Surg [Br]*. 1998;23:183–185.
14. Manske PR, McCarroll HR Jr, Swanson K. Centralization of the radial club hand: an ulnar surgical approach. *J Hand Surg [Am]*. 1981;6:423–433.
15. Vilkki SK. Distraction and microvascular epiphysis transfer for radial club hand. *J Hand Surg [Br]*. 1998;23:445–452.
16. Catagni M, Szabo RM, Cattaneo R. Preliminary experience with Ilizarov method in late reconstruction of radial hemimelia. *J Hand Surg [Am]*. 1993;18:316–321.
17. Kawabata H, Masatomi T, Yasui N. Residual deformity in congenital radial club hands after previous centralisation of the wrist: ulnar lengthening and correction by the Ilizarov method. *J Bone Joint Surg [Br]*. 1998;80:103–107.
18. Smith AA, Greene TL. Preliminary soft tissue distraction in congenital forearm deficiency. *J Hand Surg [Am]*. 1995;20:420–424.
19. Behrens F, Sabharwal S. Deformity correction and reconstructive procedures using percutaneous techniques. *Clin Orthop*. 2000;375:133–139.
20. Niall DM, Murphy PG, Fogarty EE, et al. Correction of soft tissue contractures of the wrist using the Ilizarov technique. *J Hand Surg [Br]*. 1998;23:442–444.
21. Sabharwal S. Treatment of acquired radial club hand deformity with Ilizarov apparatus. *Clin Orthop*. 2004;424:143–148.